



**PATIENT**

Pugsley Watson

**SPECIES**

Canine

**BREED**

Puggle

**SEX**

Male Neutered

**AGE**

14 years

**WEIGHT**

31lbs

**INTERPRETED BY**

Maggie Machen  
 Lamy, DVM, DACVIM  
 (Cardiology)

**IMAGING PERFORMED BY**

Jenna Walsh, CVT

**HOSPITAL NAME**

The Veterinary  
 Hospital

**REFERRING VET**

Dr. Johnson

**INVOICE**

23549

**DATE**

4/8/22

**PRESENTING CLINICAL SIGNS**

History: Cough. Dyspnea. Systolic murmur, grade 4/6. Ascites noted on AXR.  
 -Current Medications: Vetmedin 3.75mg BID, Lasix 20mg BID, Benazepril 2.5mg BID.  
 -Abnormal PE/Chem/CBC/UA Results: ALT 346, Alk Phos 605, Phos 5.5.

**RADIOGRAPHIC FINDINGS** \*NOTE: Images submitted for supplemental cardiac information only.  
 A single lateral film included. Cardiomegaly. Ascites and pleural effusion. Consistent with right-sided CHF.

**ELECTROCARDIOGRAPHIC FINDINGS** \*Note: Single lead ECGs are evaluated as a rhythm strip. Morphology/MEA cannot be definitively commented on.  
 A single lead ECG is available; 50mm/s, 20mm/mV. The average heart rate is 140bpm with a largely regular rhythm. The rhythm is sinus in origin, with a p for every QRS complex and vice versa. The P and QRS morphologies are positive. No ectopic beats, pauses or dysrhythmias observed.  
 ECG diagnosis: Normal sinus rhythm.

**ECHOCARDIOGRAM FINDINGS**

2D, m-mode, color flow and doppler imaging is available. The mitral valve is diffusely thickened with mild prolapse into the left atrial lumen. There is moderate eccentric mitral regurgitation present. The MR velocity is normal. Moderate left atrial enlargement. Borderline left ventricular dilation. Left ventricular systolic function is adequate. There is normal systolic flow velocity across the aortic valve. The aortic valve appears trileaflet with normal mobility. The main pulmonary artery is mildly dilated. Moderate right atrial and ventricular enlargement. The tricuspid valve is thickened with moderate tricuspid regurgitation. Velocity consistent with severe pulmonary hypertension. Trace pulmonic and no aortic insufficiency. No pericardial effusion. Small volume pleural effusion. No cardiac masses are seen. Hepatic congestion and ascites noted.

**CARDIAC CHART**

CANINE CARDIAC PARAMETERS	MR VMAX (m/s)	TR VMAX (m/s)	LA/AO (Boon method)	LA/AO (Heart Base; Swe)	FS (%)	EF (%)	EPSS (cm)
NORMAL PARAMETER	4.5-5.5	<2.7	1.3	<1.6	28-40	40-100	<0.6
PATIENT	5.3	4.5	1.8	1.87	58	92	NM
CANINE CARDIAC PARAMETERS	HR (BPM)	AV VMAX (m/s)	PV MAX (m/s)	BODY WEIGHT (kg)	LA 2D short axis Base view (cm)	LVIDd Avg; 2D and m-mode short axis (cm)	LVIDs Avg; 2D and m-mode short axis (cm)
NORMAL PARAMETER	50-100	0.7-1.7	0.7-1.6	BELOW	BELOW	BELOW	BELOW
PATIENT	NM	2.0	1.2	14.1	2.8	3.3	1.4
*Normal chamber parameters expressed as a mean value (SD)				3	1.27 (5.3)	2.46 (2.46)	1.36 (5.5)
<b>BODY WEIGHT DEPENDENT PARAMETERS</b>				5	1.40 (4.5)	2.74 (5.2)	1.60 (4.7)



**PATIENT**

Pugsley Watson

**SPECIES**

Canine

**BREED**

Puggle

**SEX**

Male Neutered

**AGE**

14 years

**WEIGHT**

31lbs

**INTERPRETED BY**

Maggie Machen  
Lamy, DVM, DACVIM  
(Cardiology)

**IMAGING PERFORMED BY**

Jenna Walsh, CVT

**HOSPITAL NAME**

The Veterinary  
Hospital

**REFERRING VET**

Dr. Johnson

**INVOICE**

23549

**DATE**

4/8/22

Adapted from June Boon, Veterinary Echocardiography, 1998 Rishniw M and Hollis NE, J Vet Intern Med 2000; 14:429-435 Hansson et al, Vet Rad and Ultrasound 2002 Bonagura et al. Echocardiography: principles of interpretation, Vet Clin North Am 15:1177, 1995	10	1.50 (3.8)	3.27 (3.5)	2.06 (3.1)
	15	1.83 (2.0)	3.71 (2.4)	2.43 (2.1)
	20	2.02 (1.9)	4.14 (2.2)	2.80 (2.0)
	25	2.18 (2.4)	4.48 (2.9)	3.10 (2.5)
	30	2.33 (3.3)	4.83 (3.9)	3.39 (3.4)
	35	2.48 (4.3)	5.17 (5.0)	3.69 (4.5)
	40	2.62 (5.2)	5.48 (6.1)	3.96 (5.4)
	50	2.88 (7.1)	6.07 (8.3)	4.46 (7.4)

**INTERPRETATION OF THE FINDINGS & FURTHER RECOMMENDATIONS**

Chronic degenerative valve disease causing moderate mitral and tricuspid regurgitation is identified. Moderate left atrial dilation indicates the risk for spontaneous left-sided congestive heart failure is relatively low. More importantly, there is significant pulmonary hypertension based upon the appearance of the right heart, which puts the patient at risk for right-sided congestion, and/or syncope. Given these findings, the abdominal and pleural fluid is most likely cardiogenic in origin and warrants full lifelong cardiac supportive medications including diuretics as below. The ECG is unremarkable with a normal sinus rhythm.

The underlying genesis of PAH is poorly understood in cases other than heartworm infestation, though it occurs with increased frequency in a variety of forms of chronic lung disease and in patients with idiopathic pulmonary fibrosis. Given the reported cough/gag symptom, further workup/therapy may also be useful including bronchodilators, pulmonary antibiotics, etc.

Omega fatty acid supplementation and mild salt restriction may also be of some long-term benefit. Monitor for development of a worsening cough, labored breathing, exercise intolerance or worsening collapse episodes. Monitoring of sleeping breathing rates is recommended as the best way to screen for progression to CHF at home. Unfortunately, there is high risk for spontaneous CHF, worsening cough and/or malignant arrhythmias and sudden death in the future. The prognosis with this degree of disease is poor, with most dogs able to maintain a good QOL on medications for an average of 8-12 months.

Elective anesthesia is not advised.

**PLAN**

Initiate spironolactone 1-2mg/kg PO q12h. Institute Sildenafil 1-2mg/kg PO 8h. Initiate Lasix 1-2mg/kg PO q12h. Initiate Pimobendan 0.25-0.3mg/kg PO q12h. If cough persists despite therapy, consider Hydrocodone, course of Baytril, etc. Abdominocentesis/thoracocentesis as needed for discomfort, inappetence or respiratory changes.

Recheck renal values and BP in 1-2 weeks, then every 3-4 months on diuretic therapy. If BP is >130mmHg and patient is doing well at home, institute ACEI 0.5mg/kg PO q12h (if hypotensive do not utilize).

A recheck echocardiogram is recommended in 4-6 months to screen for progression, sooner if clinical signs arise.



**PATIENT**

Pugsley Watson

**SPECIES**

Canine

**BREED**

Puggle

**SEX**

Male Neutered

**AGE**

14 years

**WEIGHT**

31lbs

**INTERPRETED BY**

Maggie Machen  
Lamy, DVM, DACVIM  
(Cardiology)

**IMAGING PERFORMED BY**

Jenna Walsh, CVT

**HOSPITAL NAME**

The Veterinary  
Hospital

**REFERRING VET**

Dr. Johnson

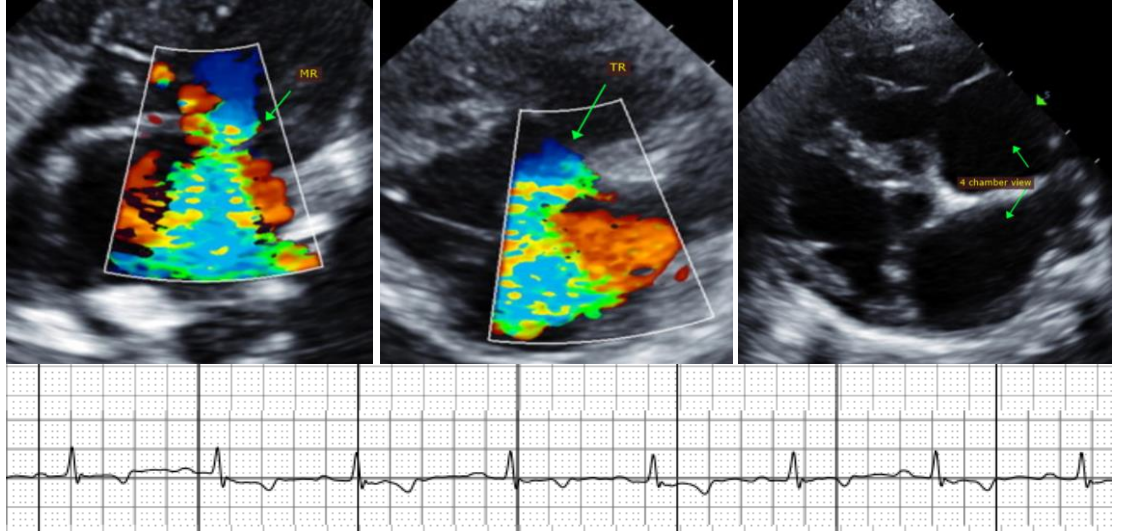
**INVOICE**

23549

**DATE**

4/8/22

**IMAGES**



The information and recommendations provided are based on the images presented by the referring veterinarian. No evaluation can be communicated regarding pathology that was not visible in the image/video clips provided.

Thank you for this referral. This report was generated using transcription software, and minor dictation errors may be present. If the clinical or image interpretation does not parallel your findings or if I can be of any further assistance, please contact me.

**Maggie Machen Lamy, DVM**  
Diplomate of the American College of Veterinary Internal Medicine (Cardiology)  
info@sonopath.com